

COVID 19 AND SPONTANEOUS PNEUMOTHORAX: A RETROSPECTIVE CASE SERIES

PERVAIZ R*¹, BIBI T¹, ARIF B¹, MUNAWAR A¹, SITARA R¹, QAYYUM MA², RAZA A³, SHAHPER A³, HAFEEZ MM³

¹Department of Critical Care, Division of Medicine, Bahria International Hospital, Lahore

²Head Department of Nephrology, Division of Medicine, Bahria International Hospital, Lahore

³Consultant Radiologist, Department of Radiology, Bahria International Hospital, Lahore

⁴Director Research and Development, Expert Doctor Private Limited, Lahore

Corresponding author email address: riwan.pervaiz@gmail.com

(Received, 2nd October 2021, Revised 1st April 2022, Published 30th April 2022)



KEYWORDS

Barotrauma, COVID-19, Non-invasive ventilation, Pneumothorax, PSILI, Patients self-induced lung injury

Received 17th October 2021;

Revised 23th April 2022;

Online 30th April 2022

Abstract: COVID-19 or severe acute respiratory distress syndrome corona virus- 2 (SARS CoV-2) is a highly infectious multi-systemic disease with severe acute pulmonary lesions leading to acute respiratory distress syndrome (ARDS) and respiratory failure as the primary complication. Spontaneous pneumothorax is an uncommon complication, but may be life-threatening and therefore have a poor prognosis. We hereby describe a series of six cases of spontaneous pneumothorax, which were seen in Bahria International Hospital corona virus management unit from July 2, 2021 to September 17, 2021 during COVID-19 surges in Lahore. These cases indicate that multiple factors are associated with development of spontaneous pneumothorax in patients of COVID-19 pneumonia. The main role is played by the increased inflammatory response and can be regarded as a potential underlying mechanism of pneumothorax in such patients, leading to acute decompensation and worsening of respiratory failure and poor outcome.

Introduction

Since the onset of COVID-19, it has caused a high degree of morbidity and mortality worldwide.

Although most cases experience mild symptoms only, but it can lead to severe acute respiratory distress syndrome requiring intensive care unit admission and respiratory support through invasive or non-invasive mechanical ventilation. Since its beginnings, COVID-19 has proven to be a multi-systemic, complex, and deadly syndrome, including pneumonia, cytokine release syndrome and clotting disorders (Bassetti et al., 2020). Over the past one and a half year more literature has emerged on the surface of evidence-based medicine about relatively uncommon presentations of disease and other related complications like spontaneous pneumothorax (Martinelli et al., 2020; Yang et al., 2020). We noted a sudden drop in saturation levels of some of the mild cases and after investigation, we found air

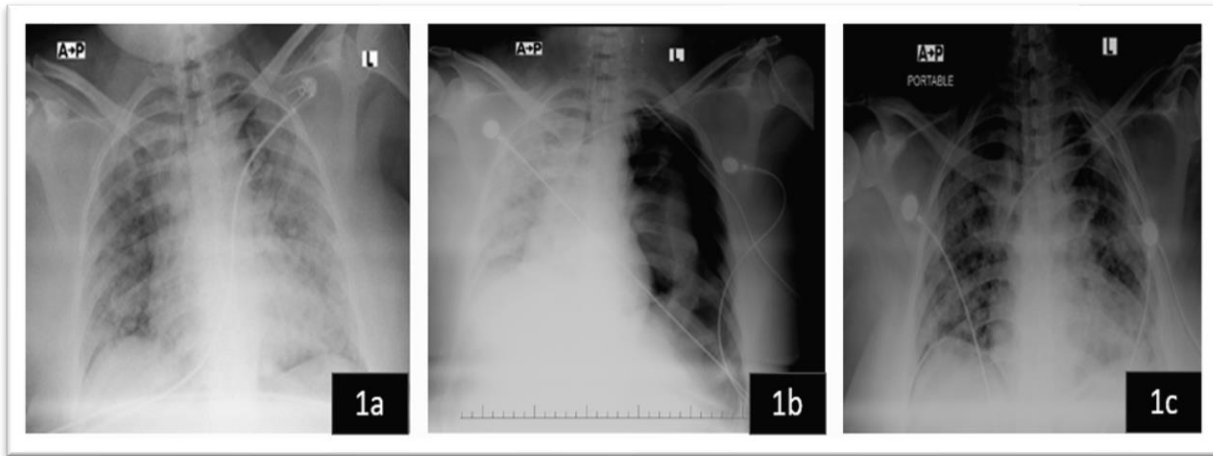
filled in plural cavity. This condition is termed as Pneumothorax. In the next section six cases of pneumothorax is reported, having COVID-19 Pneumonia.

Case 1

36 years old female, with no co-morbidities, admitted with severe respiratory failure due to COVID pneumonia with positive RT PCR. Her chest X-ray (CXR) showed bilateral infiltrates in peripheral midlung zones and bases. Her labs revealed elevated inflammatory markers. She was intubated and ventilated due to worsening hypoxia and respiratory distress. Treated with broad spectrum antibiotics, antiviral, corticosteroids, and Tocilizumab. After 5 days, she improved and was extubated successfully. She was discharged on day 10 of her admission as she was maintaining on room air. On the day when she was about to leave, she suddenly became tachypneic and developed respiratory distress due to which she was re-intubated. CXR revealed a large left sided tension

pneumothorax for which intercostal drain was placed immediately.

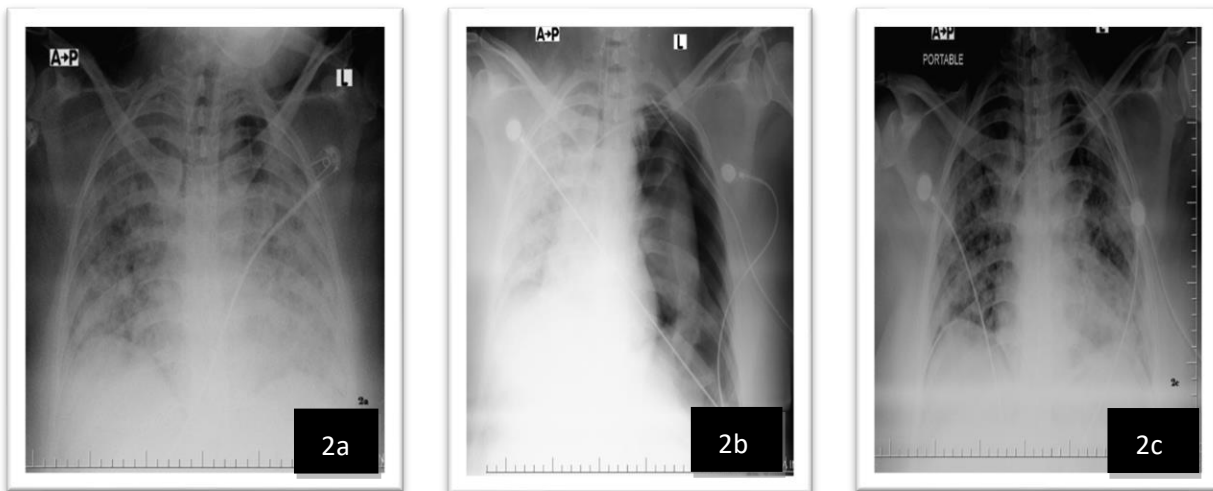
Her pneumothorax was resolved within 12 hours. (Fig 1a, 1b, 1c)



Case 2

40 years old male, with known hypertension, was admitted with severe symptoms of COVID including fever, cough and dyspnea. His nasopharyngeal swab for SARS CoV-2 was not detected. But CXR and HRCT chest showed multifocal bilateral consolidative opacities. As his laboratory studies revealed elevated inflammatory markers and Cytokines release syndrome, he was started on broad spectrum

antibiotics, antiviral, corticosteroids and Tocilizumab. Initially patient was maintaining her saturation on NRM but later he developed PSILI with left sided Pneumothorax for which ICT was passed and it was resolved. However, after few days, due to severe respiratory distress he was intubated and put on mechanical ventilation. He succumbed to septic shock and multiorgan failure.



Case 3

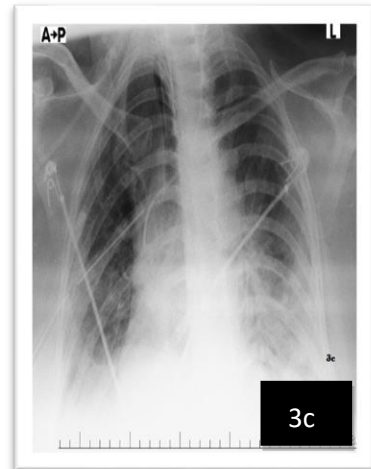
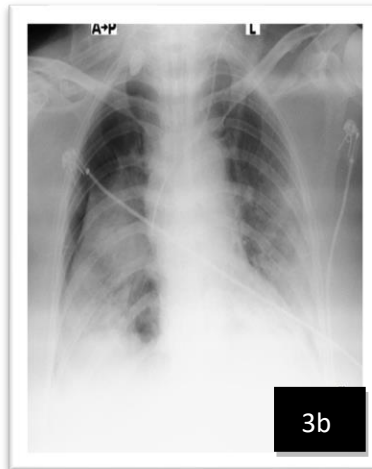
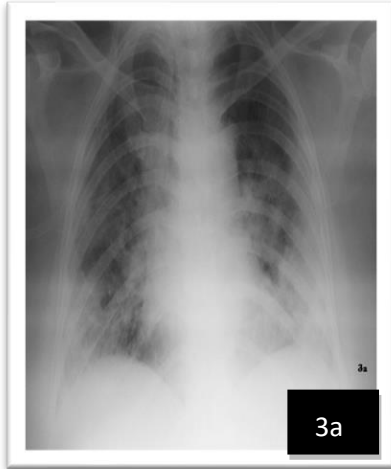
48 years old female, with no co morbidities, was admitted with symptoms of fever, cough and dyspnea. His nasopharyngeal swab for SARS Co-V 2 proved her a case of COVID 19 pneumonia. Her CXR and

HRCT showed bilateral infiltrates. 5 days later she developed severe respiratory distress, her CXR and HRCT were repeated and revealed right sided massive pneumothorax for which ICT was inserted but her pneumothorax did not resolve due to bronchopleural fistula formation. Thoracic surgery was involved to do

[Citation: Pervaiz, R., Bibi, T., Arif, B., Munawar, A., Sitara, R., Qayyum, M.A., Raza, A., Shahper, A., Hafeez MM (2022). Covid -19 and Spontaneous Pneumothorax: A Retrospective Case Series. *Pak. J. Inten. Care Med.* 2022: 10 <https://doi.org/10.54112/pjicm.v2022i1.10>]

Video assisted thoracoscopy (VATS) and lobectomy

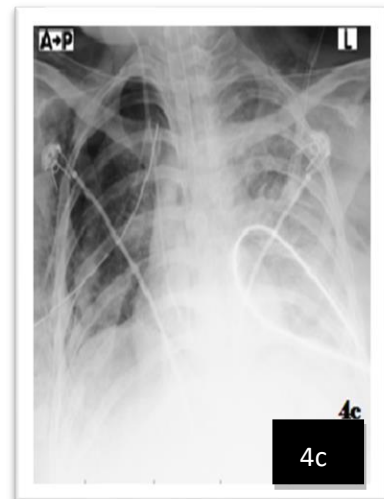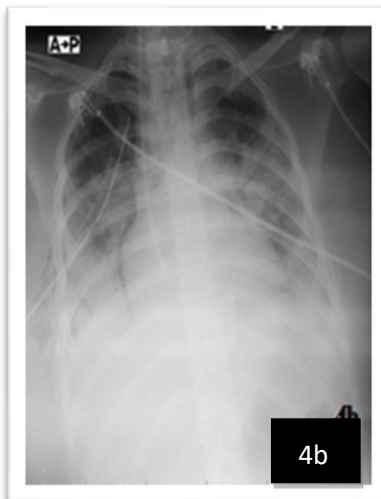
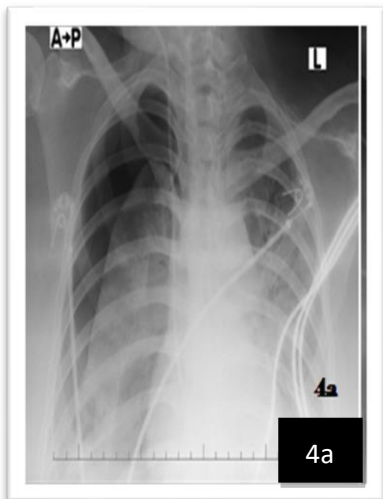was performed after which patient recovered fully.



Case 4

28-year-old female without any co-morbidities presented with symptoms of fever, cough and sever dyspnea and was diagnosed to have COVID 19 pneumonia with chest X-ray, HRCT and nasopharyngeal swab. HRCT showed dense infiltrates. 3 days later she developed respiratory distress and her

chest X ray revealed right sided massive pneumothorax for which intercostal tube was passed. She was ventilated due to respiratory distress. Her pneumothorax resolved in 24 hours but later on she expired secondary to super added infection.

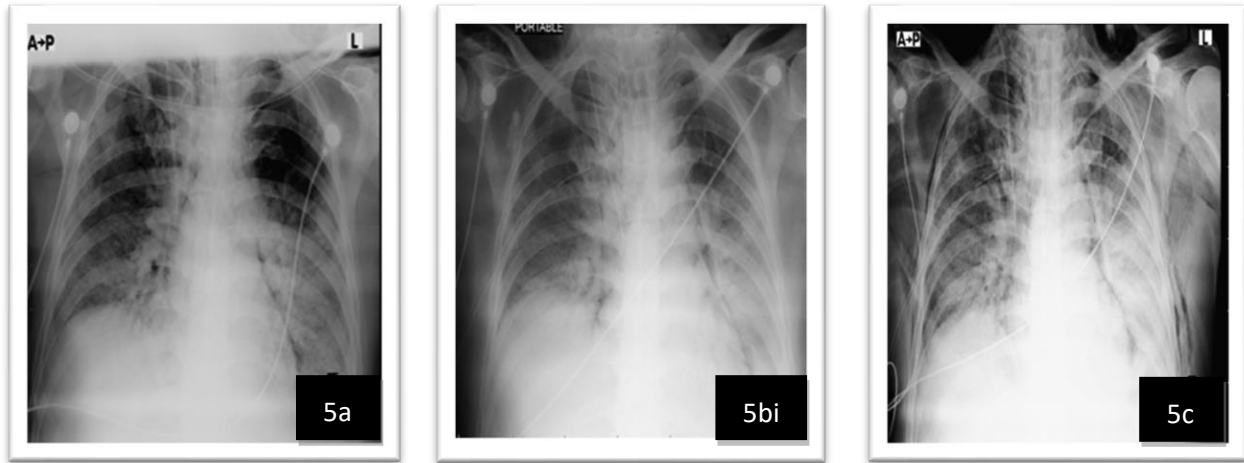


Case 5

52 years old male, known diabetic and hypertensive was admitted with fever and shortness of breath due to COVID 19 pneumonia. His chest X ray and HRCT showed bilateral multifocal dense infiltrates. His laboratory studies revealed elevated inflammatory

markers and cytokines release syndrome. He was started on standard treatment plan including antiviral, corticosteroids, antibiotics and was given Tocilizumab. After six days, developed left sided pneumothorax and surgical emphysema for which ICT was placed immediately.

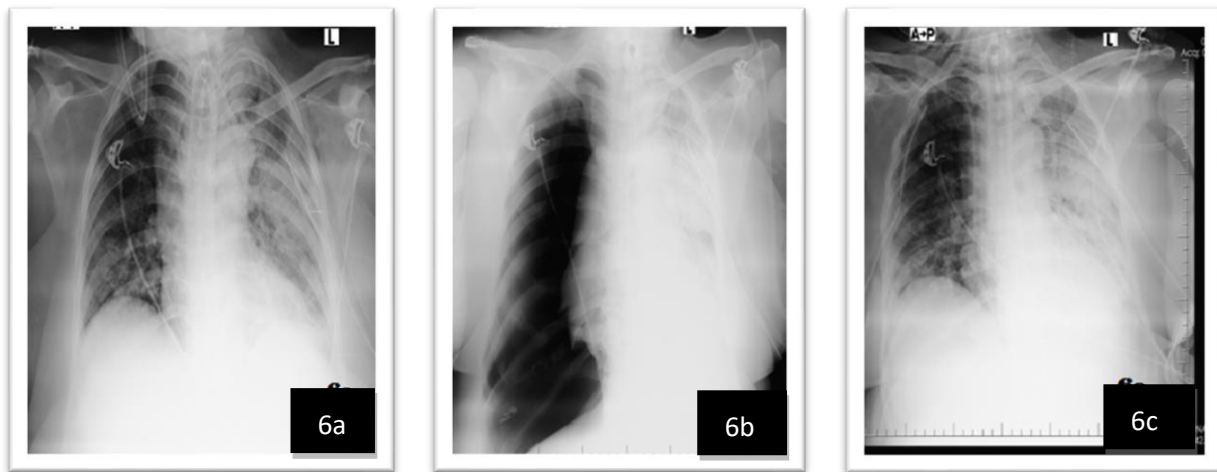
[Citation: Pervaiz, R., Bibi, T., Arif, B., Munawar, A., Sitara, R., Qayyum, M.A., Raza, A., Shahper, A., Hafeez MM (2022). Covid -19 and Spontaneous Pneumothorax: A Retrospective Case Series. *Pak. J. Inten. Care Med.* 2022: 10 <https://doi.org/10.54112/pjicm.v2022i1.10>]



Case 6:

50-year-old diabetic and hypertensive female was admitted with severe ARDS. Her nasopharyngeal swab for SARS CoV-2 was positive. Initially, she was treated with BIPAP alternating with high flow nasal

canulae but on second day she developed right sided pneumothorax for which ICT was placed and she improved.



Discussion

The exact incidence of spontaneous pneumothorax in COVID-19 patients remains undetermined though the literature depicts it to be around 1% which may rise to about 2 % in seriously sick ICU admissions (do Lago et al., 2020; Martinelli et al., 2020; Zantah et al., 2020).

The reason and association of spontaneous pneumothorax and COVID-19 is unclear and difficult to understand. If we review the disease progression through high resolution computerized tomography scans (HRCT Scans) initially the disease features

multi-lobar ground glass opacities usually involving both lungs with a predilection to more posterior and peripheral distribution, mainly in the lower lobes. Rapidly as the disease advances pleural thickening, subpleural involvement with more prominent consolidations, septal thickening, bronchiectasis, and crazy paving may be seen (Salehi et al., 2020).

By definition pneumothorax refers to the leakage of air in the pleural space from the lung and it is usually due to some definitive cause like trauma or as a result of some invasive procedure. Spontaneous pneumothorax refers to development of pneumothorax when no

[Citation: Pervaiz, R., Bibi, T., Arif, B., Munawar, A., Sitara, R., Qayyum, M.A., Raza, A., Shahper, A., Hafeez MM (2022). Covid -19 and Spontaneous Pneumothorax: A Retrospective Case Series. *Pak. J. Inten. Care Med.* 2022: 10 <https://doi.org/10.54112/pjicm.v2022i1.10>]

factor or cause could be found but an underlying lung disease or pathology is usually considered as risk factor for the development of so called (secondary) spontaneous pneumothorax (Sahn and Heffner, 2000). Our present understanding of in COVID-19 pathophysiology is limited and so is the basis of air-leakage in COVID-19. Multiple mechanisms of spontaneous pneumothorax in COVID-19 patients have been proposed including structural changes in lung parenchyma (cystic and fibrotic) which along with cytokine storm and dysregulated immune response, can contribute by causing severe lung injury, diffuse alveolar damage and may lead to alveoli rupture or tears when the diseased lung faces increased intrathoracic pressure from prolonged coughing or invasive or non-invasive mechanical ventilation. COVID-19 pneumonia (Alharthy et al., 2020; Xu et al., 2020).

Additionally, microangiopathy and thrombosis induced by the pathogenesis of COVID-19 can also cause ischemic breakdown of the alveolar wall secondary to intravascular thrombi formation (Poor et al., 2020).

Another important contributing factor is direct damage to type II pneumocytes by the virus once it gets entry into alveoli. These cells produce surfactant and impaired production of surfactant leads to stiff alveoli and lung compliance is reduced which tears when subjected to raised intra-pulmonary pressures (Hoffmann et al., 2020).

Positive end expiratory pressure (PEEP) applied in positive pressure ventilation (Invasive or NIV) increases the pressure gradient between interstitial space and alveoli and repeated inhalation and exhalation cause shear forces which may cause alveolar rupture and development of pneumothorax as the air leaks into the pleural space but the risk is low (Carron et al., 2013). Substantial evidence is now surfacing that ventilator associated barotrauma is not the primary or only factor associated with pneumothorax in COVID-19 disease but it happens through a combination of aforementioned factors leading to extensive alveolar damage and reduced lung compliance.

The risk may be potentiated by severity of symptoms like excessive coughing or increased respiratory efforts by patients to compensate ventilation perfusion mismatch (V/Q mismatch) as it may increase the intra-alveolar pressure and contribute to rupture and pneumothorax formation (Manna et al., 2020; Tucker et al., 2020).

All of our patients had elevated inflammatory markers and their CT images were consistent with severe COVID-19 disease with inflammatory response in

their lungs. The most interesting case is the one who was discharged after recovery but came back with pneumothorax and bronchopleural fistula. He underwent VATS and we found necrotizing pneumonia and the lobe had to be removed by the thoracic surgeon.

Our case series describes that lung lesions leading to pneumothorax may take weeks to develop and it seems mandatory to anticipate the complication and review the scans in detail with higher resolution to pick even minute lesions or repeat scans during the follow-up. As it can occur at any point of course of disease starting from admission revealing the disease, during hospitalization, following recovery and even after discharge from hospital (Flower et al., 2020; Touzani et al., 2021).

This case series emphasizes importance of keeping pneumothorax at top of differentials list when searching for the cause of acute deterioration in COVID-19 pneumonia patients. Clinical examination, using appropriate diagnostic tools in time including chest x-ray or point of care ultrasound (POCUS) can not only expedite the diagnosis but can save lives by directing the treating clinicians towards right course of action. While draining the pneumothorax negative pressure suction (around -20 cm of H_2O) are recommended to decrease the risk of iatrogenic infection (Consoli et al., 2020; Li et al., 2021; López Vega et al., 2020; McGuinness et al., 2020).

Conclusion

Pneumothorax in COVID-19 patients not only prolongs hospital stay but is also associated with may be associated with worse outcome. Hence, its emergent identification and management is important as well as its prevention by avoiding high pressures settings or adjusting them appropriately in timely identified individuals through meticulous screening via imaging is the key to better outcomes.

Reference

- Alharthy, A., Faqih, F., Memish, Z. A., and Karakitsos, D. (2020). Lung injury in COVID-19—an emerging hypothesis. *ACS chemical neuroscience* **11**, 2156-2158.
- Bassetti, M., Vena, A., and Giacobbe, D. R. (2020). The novel Chinese coronavirus (2019-nCoV) infections: Challenges for fighting the storm. *European journal of clinical investigation* **50**.

- Carron, M., Freo, U., BaHammam, A., Dellweg, D., Guarracino, F., Cosentini, R., Feltracco, P., Vianello, A., Ori, C., and Esquinas, A. (2013). Complications of non-invasive ventilation techniques: a comprehensive qualitative review of randomized trials. *British journal of anaesthesia* **110**, 896-914.
- Consoli, L., Bendotti, V., Cicchinelli, S., Gaioni, F., Prandolini, P., Bettonagli, M., and Terragnoli, P. (2020). 2019 novel coronavirus (COVID-19) pneumonia complications: the importance of lung ultrasound. *Journal of ultrasound*, 1-4.
- do Lago, V. C., Cezare, T. J., Fortaleza, C. M. C. B., Okoshi, M. P., Baldi, B. G., and Tanni, S. E. (2020). Does COVID-19 increase the risk for spontaneous pneumothorax? *The American journal of the medical sciences* **360**, 735-737.
- Flower, L., Carter, J.-P. L., Lopez, J. R., and Henry, A. M. (2020). Tension pneumothorax in a patient with COVID-19. *BMJ Case Reports CP* **13**, e235861.
- Hoffmann, M., Kleine-Weber, H., Schroeder, S., Krüger, N., Herrler, T., Erichsen, S., Schiergens, T. S., Herrler, G., Wu, N.-H., and Nitsche, A. (2020). SARS-CoV-2 cell entry depends on ACE2 and TMPRSS2 and is blocked by a clinically proven protease inhibitor. *cell* **181**, 271-280. e8.
- Li, W., Xu, S., Li, P., Wang, G., and Wang, Z. (2021). Pneumothorax in 2019 novel coronavirus pneumonia needs to be recognized. *Infection* **49**, 367-368.
- López Vega, J. M., Parra Gordo, M. L., Diez Tascón, A., and Ossaba Vélez, S. (2020). Pneumomediastinum and spontaneous pneumothorax as an extrapulmonary complication of COVID-19 disease. *Emergency Radiology* **27**, 727-730.
- Manna, S., Maron, S. Z., Cedillo, M. A., Voutsinas, N., Toussie, D., Finkelstein, M., Steinberger, S., Chung, M., Bernheim, A., and Eber, C. (2020). Spontaneous subcutaneous emphysema and pneumomediastinum in non-intubated patients with COVID-19. *Clinical imaging* **67**, 207-213.
- Martinelli, A. W., Ingle, T., Newman, J., Nadeem, I., Jackson, K., Lane, N. D., Melhorn, J., Davies, H. E., Rostron, A. J., and Adeni, A. (2020). COVID-19 and pneumothorax: a multicentre retrospective case series. *European Respiratory Journal* **56**.
- McGuinness, G., Zhan, C., Rosenberg, N., Azour, L., Wickstrom, M., Mason, D. M., Thomas, K. M., and Moore, W. H. (2020). Increased incidence of barotrauma in patients with COVID-19 on invasive mechanical ventilation. *Radiology* **297**, E252-E262.
- Poor, H. D., Ventetuolo, C. E., Tolbert, T., Chun, G., Serrao, G., Zeidman, A., Dangayach, N. S., Olin, J., Kohli-Seth, R., and Powell, C. A. (2020). COVID-19 critical illness pathophysiology driven by diffuse pulmonary thrombi and pulmonary endothelial dysfunction responsive to thrombolysis. *Clinical and Translational Medicine* **10**, e44.
- Sahn, S. A., and Heffner, J. E. (2000). Spontaneous pneumothorax. *New England Journal of Medicine* **342**, 868-874.
- Salehi, S., Abedi, A., Balakrishnan, S., and Gholamrezaezhad, A. (2020). Coronavirus disease 2019 (COVID-19): a systematic review of imaging findings in 919 patients. *Ajr Am J Roentgenol* **215**, 87-93.
- Touzani, S., Kabbat, M., Zoulgami, H., Houari, N., Elbouazzaoui, A., Boukatta, B., and Kanjaa, N. (2021). Pneumothorax complicating COVID-19 pneumonia: A case report and review. *Int J Case Rep Images* **12**, 101214Z01ST2021.
- Tucker, L., Patel, S., Vatsis, C., Poma, A., Ammar, A., Nasser, W., Mukkera, S., Vo, M., Khan, R., and Carlan, S. (2020). Pneumothorax and pneumomediastinum secondary to COVID-19 disease unrelated to mechanical ventilation. *Case reports in critical care* **2020**.
- Xu, Z., Shi, L., Wang, Y., Zhang, J., Huang, L., Zhang, C., Liu, S., Zhao, P., Liu, H., and Zhu, L. (2020). Pathological findings of COVID-19 associated with acute respiratory distress syndrome. *The Lancet respiratory medicine* **8**, 420-422.
- Yang, X., Yu, Y., Xu, J., Shu, H., Liu, H., Wu, Y., Zhang, L., Yu, Z., Fang, M., and Yu, T. (2020). Clinical course and outcomes of critically ill patients with SARS-CoV-2 pneumonia in Wuhan, China: a single-centered, retrospective, observational study. *The Lancet Respiratory Medicine* **8**, 475-481.
- Zantah, M., Dominguez Castillo, E., Townsend, R., Dikengil, F., and Criner, G. J. (2020). Pneumothorax in COVID-19 disease-incidence and clinical characteristics. *Respiratory Research* **21**, 1-9.



Open Access This article is licensed under a Creative Commons Attribution 4.0 International License, which permits use, sharing, adaptation, distribution and reproduction in any medium or format, as long as you give appropriate credit to the original author(s) and the source, provide a link to the Creative Commons licence, and indicate if changes were made. The images or other third party material in this article are included in the article's Creative Commons licence, unless indicated otherwise in a credit line to the material. If material is not included in the article's Creative Commons licence and your intended use is not permitted by statutory regulation or exceeds the permitted use, you will need to obtain permission directly from the copyright holder. To view a copy of this licence, visit <http://creativecommons.org/licenses/by/4.0/>.

© The Author(s) 2022