

COMPLETE REVERSAL OF TRANS-TENTORIAL AND SUB-FALCINE BRAIN HERNIATION WITH CRANIECTOMY: A SUCCESSFUL CASE REPORT

PERVAIZ R^{1*}, HAFEEZ T¹, RAZA N², RAZA A³, AQEEL S³, SHAHID MJ³, AHMED M⁴, ABEDIN SMZU¹, ASHRAF A⁴, RUBEET A⁴

¹Department of Medicine and Critical Care, Bahria International Hospital, Lahore, Pakistan

²Department of Neurosurgery, Bahria International Hospital, Lahore, Pakistan

³Department of Radiology, Bahria International Hospital, Lahore, Pakistan

⁴Research and Innovation, Department of Critical Care Medicine, Bahria International Hospital, Lahore

*Corresponding author's email address: drizwanpervaiz@gmail.com

(Received, 28th April 2024, Revised 26th June 2024, Accepted 2nd July 2024, Published 5th July 2024)

ABSTRACT

Introduction: Brain herniation, or brain code, is a critical condition caused by elevated intracranial pressure, leading to abnormal brain tissue protrusion. Chronic herniations may be linked to developmental defects and remain asymptomatic, while acute herniations are life-threatening, especially after neurosurgery. **Case Presentation:** A 25-year-old female with Glioblastoma multiforme presented with facial weakness. Initially suspected as Bell's Palsy, her condition rapidly worsened, leading to coma and signs of raised intracranial pressure. A CT scan revealed a brain tumor with associated edema, hemorrhage, and multiple herniations. Emergency craniectomy and subsequent medical management showed initial improvement, but she later developed ischemia and infarction, resulting in her death. **Discussion:** Timely diagnosis and intervention are crucial in managing brain herniation. Clinical signs and cranial nerve assessments are vital for diagnosis. Management focuses on reducing intracranial pressure through medical and surgical means. Early intervention is key to better outcomes, though the prognosis can be poor due to underlying conditions like Glioblastoma multiforme. **Conclusion:** Effective management of brain herniation requires timely surgical and medical intervention. This case illustrates the rapid progression and complexity of brain herniation, emphasizing the importance of early and comprehensive treatment.

Keywords: Brain Herniation, Glioblastoma Multiforme, Intracranial Pressure

INTRODUCTION

Brain herniation or brain code is a life-threatening event requiring emergent attention. Brain herniation is the result of a series of events that start from raised intracranial pressure and lead to the eventual abnormal protrusion of brain tissue through the rigid dural folds (i.e., falx and tentorium) &/or skull openings (e.g., foramen magnum) (1-3).

Chronic brain herniations have shown associations with developmental defects such as Arnold–Chiari malformation and they may not become symptomatic for several years (4). Acute brain herniation on the other hand is a life-threatening event that can cause mechanical and vascular damage to the brain, especially following a neurosurgery (5).

Tentorium is an extension of the dura mater that separates the cerebrum and the cerebellum. Several different types of herniations have been studied and described in relation to tentorium. The tentorial notch (6) is an opening between the free edge of the tentorium cerebelli and the clivus for the passage of the brainstem anteriorly. Several important anatomical structures pass through the tentorial notch including the midbrain, third cranial nerve, posterior cerebral arteries, and superior cerebellar arteries. The cerebellum resides in the posterior portion of the notch.

There are two major classes of herniation: supratentorial and infratentorial. Supratentorial refers to the herniation of structures normally above the tentorial notch, and infratentorial refers to structures below it (3).

• Supratentorial herniation is further sub-classified as follows:

1. Uncal (trans-tentorial)

2. Central
3. Cingulate (sub-falcine/trans-falcine)
4. Trans-calvarial
5. Tectal (posterior)
- Infratentorial herniation is also sub-classified as mentioned:
5. Upward (upward cerebellar or upward trans-tentorial)
6. Tonsillar (downward cerebellar)

Uncal or Trans-tentorial Herniation:

The uncus is a structure present at the antero-medial aspect of the Parahippocampal gyrus in the medial temporal region of the brain, within the supra-tentorium. The continuously rising intracranial pressure can result in portions of the brain to flow from one intracranial compartment to another increasing the risk of uncal herniation. This is a neurosurgical emergency and indicates the failure of all physiological adaptations for intracranial compliance (1).

Brain tissue combined with arterial &/or venous blood, and CSF make up the intracranial compartment. The Monro-Kellie principle states that an increase in any of these components should and will come at the expense of another (2). This means that a mass present in the supratentorial compartment would cause the reduction of CSF and venous blood volume, following which the arterial blood flow and total volume would also decrease eventually risking the herniation of brain tissue through existing cranial openings.

Hence, any situation that results in a significantly increased intracranial pressure poses a threat to cause an uncal herniation. This is especially true for the space-occupying lesions that leave the patients at risk for such herniations by the pathophysiological process

[Citation: Pervaiz, R., Hafeez, T., Raza, N., Raza, A., Aqeel, S., Shahid, M. J., Ahmed, M., Abedin, S. M. Z. U., Ashraf, A., Rubeet, A. (2024). Complete reversal of trans-tentorial and sub-falcine brain herniation with craniectomy: a successful case report. *Pak. J. Inten. Care Med.* 2024: 32. doi: <https://doi.org/10.54112/pjicm.v4i02.32>]

mentioned above. Subdural or epidural hematoma formed as a result of direct and severe head trauma usually occupy the lateral middle fossa or temporal lobe can be rapidly expanding and increase the risk of uncal herniation by many folds. Uncal herniations are the end product of the catastrophic force in the supratentorial region generated by a rapid increase in intracranial pressure that causes the uncus to slide over the supratentorial notch (4, 7, 8)

The herniating uncus pushes against the brainstem and the corresponding cranial nerves, particularly causing the third cranial nerve that is located medial to the uncus to become entrapped (9, 10). The herniation can also occlude PCA (as with central herniation) (6).

Central Herniation:

Central herniation occurs when the diencephalon and parts of the temporal lobes of both of the cerebral hemispheres are pushed through a notch in the tentorium cerebelli (5).

Cingulate or sub-falcine herniation:

This is the most common type of brain herniation and is caused by the scraping of the innermost part of the frontal lobe under a part of the falx cerebri which is the dura mater at the top of the head between the two hemispheres of the brain (11).

Trans-calvarial herniation:

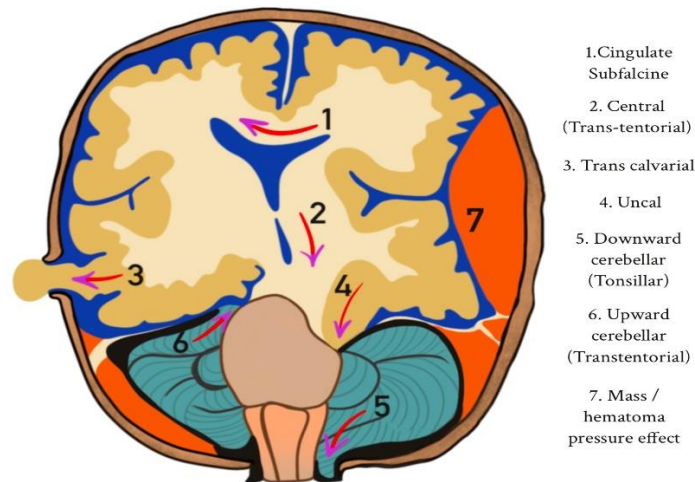
Also called the external herniation, trans-calvarial herniation happens when the brain squeezes through a fracture or a surgical site in the skull. This usually happens during a craniectomy when the protruding brain section prevents the removal of the cranium (12, 13).

Upward cerebellar herniation:

Upward herniation takes place when increased pressure in the posterior fossa causes the cerebellum to move upward through the tentorial opening (9).

Tonsillar or downward cerebellar herniation:

In tonsillar herniation, also called downward cerebellar herniation, transforaminal herniation, or "coning", the cerebellar tonsils slide through the foramen magnum risking the compression of the lower brainstem and upper cervical spinal cord as they navigate through that region. This can cause damage to the respiratory and cardiac control centers in brainstem and severe headache, trismus, and neck rigidity due to tonsillar entrapment. The consciousness may also falter that puts the patient at risk for flaccid paralysis. Another defining feature of this disorder is the fluctuations in patient's blood pressure (14).



Diagnosis;

The diagnosis of uncal herniation is mainly clinical that is confirmed with brain imaging. Neurological examination including the assessment of cranial nerves is the single most important thing pointing towards the diagnosis. A unilaterally dilating pupil is the earliest hallmark feature of this disorder. It is unlikely that a patient undergoing early uncal herniation would be completely neurologically intact except for anisocoria. Contralateral motor weakness is a frequent association. Ipsilateral involvement can also be seen in rare cases as defined by the Kernohan Notch Phenomenon and result in false localizing signs. Impaired consciousness, even though an unreliable sign, can be seen early in the disease course (15). Another concerning feature that is frequently seen in association with the herniation is the development of Cushing's triad (widened pulse pressure, bradycardia, and irregular respirations). This is considered an indication for an immediate CT scan to rule out fatal hemorrhage, herniation, or mass

lesion (1, 14). A cranial CT scan is the preferred imaging modality over magnetic resonance imaging (MRI) in the emergent setting; it can be completed quickly, and CT imaging technology is more readily available. (1, 14)

Treatment:

Following the development of signs and symptoms of uncal herniation, the volume of one component of the intracranial compartment, either brain, blood, or cerebrospinal fluid must be adjusted to bring the ICP down (8).

Management strategies to achieve this include:

- Elevating the head of the bed thirty degrees
- Keeping the head midline
- Hyperventilation
- Hyperosmolar therapy with either mannitol or hypertonic saline (16)

Surgical options may be considered for decompression if the clinical signs of uncal herniation do not resolve with the supportive strategies. These include:

- Placement of a ventricular drain

- Evacuation of an extra-axial lesion such as an epidural hematoma
- Resection of an intracerebral lesion
- Removal of brain parenchyma
- Uni- or bilateral craniectomies (17).

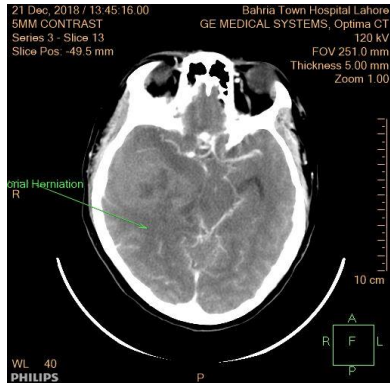
This case report presents a unique and challenging case of Glioblastoma multiforme which transformed into a brain herniation, managed with an immediate craniectomy.

Case report:

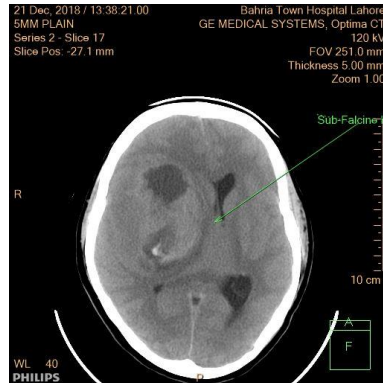
A 25-year-old female, previously diagnosed with Glioblastoma multiforme, had presented to the Medical Outpatient Department with complaints of asymmetrical facial weakness and unilateral drooping of

the mouth. Based on an early suspicion of Bell’s Palsy, she was prescribed oral steroids and was scheduled for a follow-up in 3 days. However, that same day she presented to the Emergency Room in a coma, exhibiting shallow breathing, a heart rate of below 60 beats per minute, and a widened pulse pressure. The neurological assessment revealed a score less than 7 on the Glasgow Coma Scale and her pupils were non-reactive bilaterally.

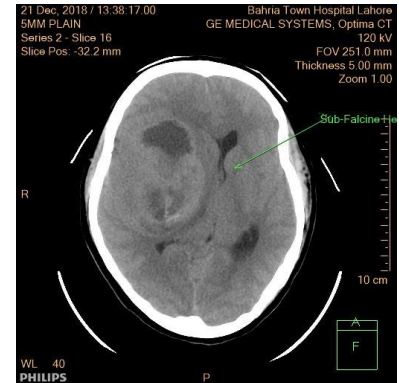
The clinical signs suggested increased intracranial pressure, prompting an immediate brain CT scan. Her brain tumor was identified in the right cerebral hemisphere in the frontotemporal lobes. Notably, however, there was also surrounding edema, internal hemorrhage, and complete effacement of the lateral ventricle on the ipsilateral side. A right-sided trans-tentorial herniation (Figure 1a) resulted in the displacement of the brainstem towards the left side, with additional findings of sub-falcine (Figures 1b and 1c) and tonsillar herniations.



1(a)



1(b)



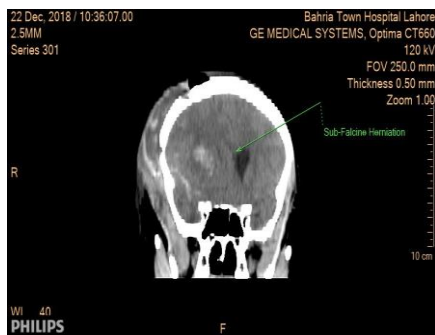
1(c)

Figure 1: Neuroimaging of a 25-year-old female with Glioblastoma multiforme. (a) Right-sided trans-tentorial herniation demonstrating displacement of the brainstem towards the left. (b) Sub-falcine herniation with midline shift. (c) Tonsillar herniation showing downward displacement of the cerebellar tonsils.

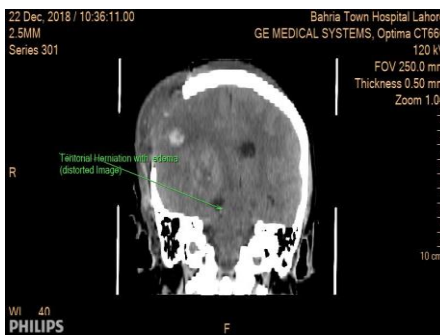
Following the CT scan, an urgent neurosurgical consultation led to the patient undergoing an immediate craniectomy that same night. Given the expected prolonged requirement for mechanical ventilation, an early tracheostomy was also performed. The patient was subsequently transferred to the Medical Intensive Care Unit, where she remained under mechanical ventilation, medically sedated, and paralyzed. Ventilation settings were adjusted to decrease the arterial

carbon dioxide levels through hyperventilation.

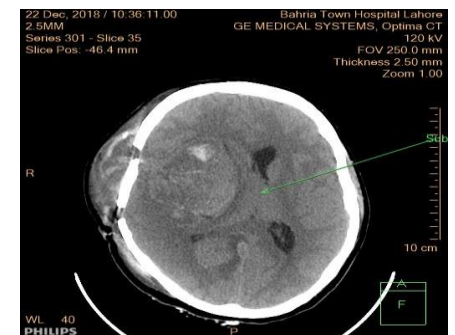A repeat CT scan conducted the next day revealed the presence of a craniectomy defect and a corresponding sub-galeal hematoma (Figures 2a, 2b, and 2c). However, there was no significant improvement or signs of reversal of herniation at that time. Over the next 3 days, daily neurological evaluations were performed to assess her status and monitor her condition.



2(a)



2(b)



2(c)

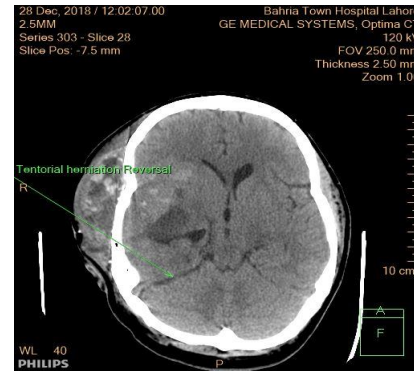
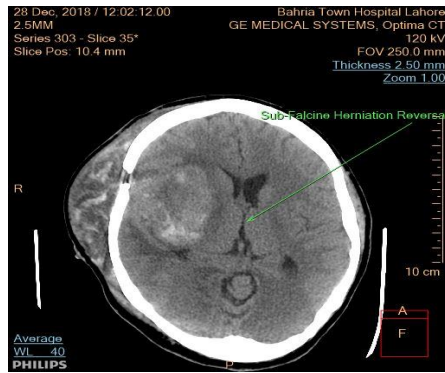
Figure 2: Post-operative imaging following emergency craniectomy in a 25-year-old female with Glioblastoma multiforme. (a) CT scan showing the craniectomy defect. (b) Sub-galeal hematoma formation. (c) Persistent herniation with no significant improvement or reversal signs.

On her 5th post-operative day, sedatives and paralytics were

discontinued to assess her Glasgow Coma Scale, which by then had

improved dramatically. A wean-off trial was initiated, and she was successfully liberated from mechanical ventilation on the same day.

Owing to her clinical improvement, a 3rd CT scan was then done which also showed signs of reversal of herniation (Figures 3a and 3b).



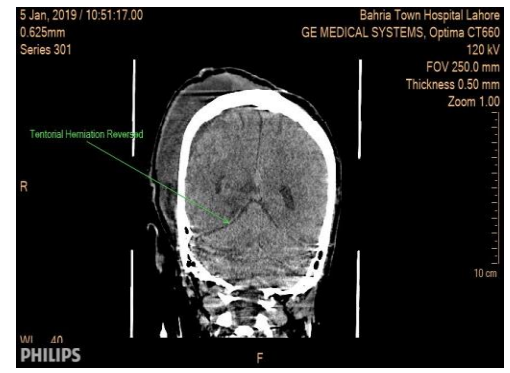
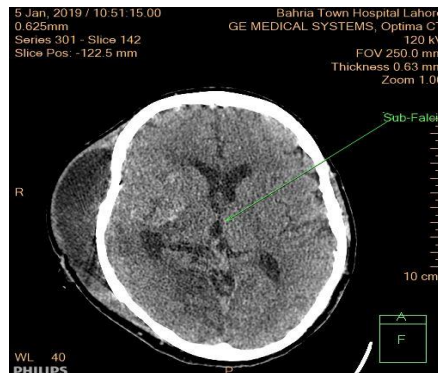
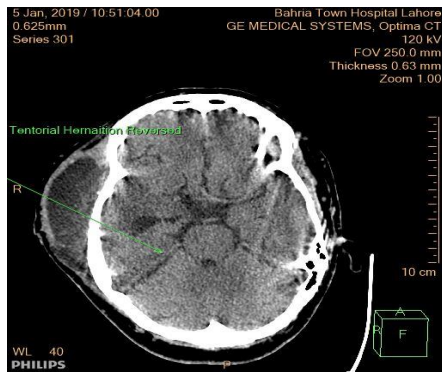
3(a)

3(b)

Figure 3: Neuroimaging on the 5th post-operative day showing improvement following craniectomy in a 25-year-old female with Glioblastoma multiforme. (a) CT scan indicating signs of reversal of the right-sided trans-tentorial herniation. (b) CT scan showing resolution of sub-falcine and tonsillar herniations.

Effacement of right lateral ventricle had markedly decreased, midline shift had decreased by 1.5mm (shift of 6.8mm in latest scan, compared to 8.3mm in the first scan), and mass effect over brain stem had significantly reduced. Trans-tentorial herniation

had seemed to reverse completely, however there was still mild sagging of the right cerebellar tonsil below the opisthion basal line for 2.6mm. However, the imaging showed complete reversal of herniations by fortnight (Figures 4a, 4b, and 4c)



4(a)

4(b)

4(c)

Figure 4: Follow-up neuroimaging showing complete reversal of herniations by fortnight in a 25-year-old female with Glioblastoma multiforme. (a) Markedly decreased effacement of the right lateral ventricle. (b) Reduction of midline shift to 6.8mm from an initial 8.3mm. (c) Significant reduction in mass effect over the brainstem and complete reversal of trans-tentorial herniation, with only mild sagging of the right cerebellar tonsil.

Unfortunately, her clinical recovery was short-lived, as her latest scan revealed signs of ischemia, infarction, and subarachnoid hemorrhage. The aggressive nature of her brain tumor ultimately led to her demise over the ensuing days.

DISCUSSION

Brain herniation is a life-threatening event that can lead to rapid clinical deterioration, and thus requires emergent diagnosis to timely counter the disastrous complications and prevent mortality and reduce morbidity.

Signs of increased intracranial pressure, particularly the Cushing triad may be observed in most patients, and other distinct neurological signs may be present depending on the type of herniation. Furthermore, any patient presenting with

confusion, agitation, or altered mental status should not be dismissed. Once brainstem findings appear, deterioration may be rapid (deep coma may occur within hours) with progression of raised intracranial pressure (18). After initial management of the patient’s airway, breathing and circulation, the next step is to order a cranial CT.

Once the diagnosis of brain herniation has been established, management is directed towards decreasing intracranial pressure. Patients are mechanically ventilated and kept sedated and paralyzed to avoid agitation. Tidal volume or respiratory rate is increased, with a target PaCO₂ of 30-35 mmHg. Hyperventilation works to reduce the intracranial pressure by decreasing arterial carbon dioxide levels which will induce vasoconstriction and therefore reduce the cerebral blood volume. Hyperosmolar therapy with mannitol or 3% hypertonic

[Citation: Pervaiz, R., Hafeez, T., Raza, N., Raza, A., Aqeel, S., Shahid, M. J., Ahmed, M., Abedin, S. M. Z. U., Ashraf, A., Rubeet, A. (2024). Complete reversal of trans-tentorial and sub-falcine brain herniation with craniectomy: a successful case report. *Pak. J. Inten. Care Med.* 2024: 32. doi: <https://doi.org/10.54112/pjicm.v4i02.32>]

saline is administered to patients with intracranial pressure above 20 mmHg or when there is suspected brain herniation. Mannitol is given as a bolus dose of 0.5-1 g/kg and can be administered every four hours as needed for intracranial pressures above 20 mmHg, maintaining an osmolar gap of less than 20 mOsm. 3% hypertonic saline is given as a bolus dose of 5-10 mL/kg in patients with acute elevations of intracranial pressure or with signs of brain herniation. Hypertonic saline can be administered as a continuous infusion at 0.5-1.5 mL/kg/hr (15-17). In patients with malignancies and abscesses, corticosteroids may reduce vasogenic edema. (19)

The role of early surgical intervention in the management of brain herniation is controversial, and the benefits must be weighed against the risks of major brain surgery (15). Nevertheless, the decision for surgical intervention should be made promptly, and an important factor for a better neurosurgical outcome in patients with uncal herniation is early diagnosis and timely management of the condition. (20, 21)

The degree of herniation will also affect the prognosis of patients with uncal herniation. The reversibility of the herniation becomes more difficult in patients with multiple traumas or when new complications arise as herniation increases. However, reversal of uncal herniation can be achieved if the interventions commence rapidly. Reversal of uncal herniation is known to occur in 50–75% of adult patients with either traumatic brain injury or with supratentorial mass lesions. Long-term outcomes after successful treatment for herniation may be more favorable in children than in adults. (20, 21)

CONCLUSION

Multiple strategies to reduce intracranial pressure exist to choose from. The choice between medical management versus surgical management is a tough one, and must be tailored to the clinical condition of the patient. Our patient initially presented with facial asymmetry, however, her clinical condition drastically deteriorated the same day. Urgent craniectomy, supplemented with medical management and targeted ventilation settings resulted in a dramatic improvement in her condition

DECLARATIONS

Data Availability statement

All data generated or analyzed during the study are included in the manuscript.

Ethics approval and consent to participate

Approved by the department Concerned.

Consent for publication

Approved

Funding

Not applicable

CONFLICT OF INTEREST

The authors declared the absence of a conflict of interest.

AUTHOR CONTRIBUTION

RIZWAN PERVAIZ

Conception of Study, Review of manuscript

TAYYABA HAFEEZ

Review of Literature

NASIR RAZA

Drafting article

AHMAD RAZA, SHAHPER AQEEL, MUHAMMAD JAZIB SHAHID, MUHAMMAD AHMED

Manuscript revisions, critical input.

SYED MUHAMMAD ZAIN UL ABEDIN

collaborative efforts, Methodology Design

ALEENA ASHRAF, AHMAD RUBEET

Drafting article, Review of manuscript

REFERENCES

1. Cadena R, Shoykhet M, Ratcliff JJ. Emergency neurological life support: intracranial hypertension and herniation. *Neurocritical Care*. 2017;27:82-8.
2. Lv X, Wu Y, Liang S. *Frontiers in Hydrocephalus: BoD—Books on Demand*; 2023.
3. Markova V, Ganchev T, Filkova S, Markov M. MMD-MSD: A Multimodal Multisensory Dataset in Support of Research and Technology Development for Musculoskeletal Disorders. *Algorithms*. 2024;17(5):187.
4. Udayakumaran S, Ben Sira L, Constantini S. Chronic uncal herniation secondary to posterior fossa shunting: case report and literature review. *Child's Nervous System*. 2010;26:267-71.
5. Innes JRM, Saunders LZ. *Comparative neuropathology*: Elsevier; 2013.
6. Rhoton Jr AL. Tentorial incisura. *Neurosurgery*. 2000;47(3):S131-S53.
7. Godoy DA, Lubillo S, Rabinstein AA. Pathophysiology and management of intracranial hypertension and tissular brain hypoxia after severe traumatic brain injury: an integrative approach. *Neurosurgery Clinics*. 2018;29(2):195-212.
8. Mokri B. The Monro–Kellie hypothesis: applications in CSF volume depletion. *Neurology*. 2001;56(12):1746-8.
9. Center VBI. Care of the Patient with Mild Traumatic Brain Injury. 2011.
10. McCaffrey P. The Neuroscience on the Web Series: CMSD 336 Neuropathologies of Language and Cognition. California State University, Chico Retrieved on February. 2001;6:2007.
11. Suyasa AB, Rahardjo S. Penanganan Edema Serebri Berat dan Herniasi Serebri pada Cedera Kepala Traumatik. *Jurnal Neuroanestesi Indonesia*. 2012;1(2):110-19.
12. Packet SL. Overview of adult traumatic brain injuries. Orlando Regional Healthcare, Education & Development, Orlando, FL. 2004.
13. Patel J. Level 1 versus level 2 trauma centers in the treatment of traumatic brain injury: Boston University; 2018.
14. Schimpf MM. Diagnosing increased intracranial pressure. *Journal of Trauma Nursing* JTN. 2012;19(3):160-7.
15. Lan Z, Richard SA, Li Q, Wu C, Zhang Q, Chen R, et al. Outcomes of patients undergoing craniotomy and decompressive

craniectomy for severe traumatic brain injury with brain herniation: a retrospective study. *Medicine*. 2020;99(43):e22742.

16. Wijdicks EF, Schievink WI, McGough PF. Dramatic reversal of the uncus syndrome and brain edema from infarction in the middle cerebral artery territory. *Cerebrovascular Diseases*. 1997;7(6):349-52.

17. Stocchetti N, Taccone FS, Citerio G, Pepe PE, Le Roux PD, Oddo M, et al. Neuroprotection in acute brain injury: an up-to-date review. *Critical care*. 2015;19:1-11.

18. Maramattom BV, Wijdicks EF. Uncus herniation. *Archives of neurology*. 2005;62(12):1932-5.

19. Das JM, Bajaj J. Pneumocephalus. *StatPearls [Internet]*: StatPearls Publishing; 2023.

20. Uzan M, Yentur E, Hanci M, Kaynar M, Kafadar A, Sarioglu A, et al. Is it possible to recover from uncus herniation? *Journal of neurosurgical sciences*. 1998;42:89-94.

21. Qureshi AI, Geocadin RG, Suarez JL, Ulatowski JA. Long-term outcome after medical reversal of transtentorial herniation in patients with supratentorial mass lesions. *Critical care medicine*. 2000;28(5):1556-64.



Open Access This article is licensed under a Creative Commons Attribution 4.0 International License, which permits use, sharing, adaptation, distribution and reproduction in any medium or format, as long as you give appropriate credit to the original author(s) and the source, provide a link to the Creative Commons licence, and indicate if changes were made. The images or other third party material in this article are included in the article's Creative Commons licence, unless indicated otherwise in a credit line to the material. If material is not included in the article's Creative Commons licence and your intended use is not permitted by statutory regulation or exceeds the permitted use, you will need to obtain permission directly from the copyright holder. To view a copy of this licence, visit <http://creativecommons.org/licenses/by/4.0/>. © The Author(s) 2024